

# Application of Microwave against Protoscoleces of Echinococcus Granulosus in Vitro and Secondary Hydatid Disease in BALB/C Mice

Seham Ibrahim Khalil<sup>1</sup>, Asmaa Abdulaziz Ali<sup>2</sup>

<sup>1,2</sup>Department of Biology/Education College for Pure Sciences/ University of Mosul/Iraq

Email: [seham.esp57@student.uomosul.edu.iq](mailto:seham.esp57@student.uomosul.edu.iq)

## Abstract

The present research investigated the impact of microwave of (230-240V-50Hz 900W) on the viability of Echinococcus granulosus protoscoleces in vitro, for different exposing periods, 3, 5, 7, 10, 12, 13, 15 seconds, respectively, subsequently prevention of mice against infestation with secondary hydatid cysts, in comparison with the control animals infested with protoscoleces without exposure to microwaves, along four months, depending on many criteria including the numbers, weights and diameters of developed hydatid cysts. The results revealed an obvious infl of microwaves on Echinococcus granulosus protoscoleces viability by increase of exposure period in vitro, 90%, 80%, 77%, 70%, 50, 30 and 0%, respectively, in addition to a decrease of 97%, 92.5% of hydatid cysts numbers in the mice injected with exposed protoscoleces with 30% fertility exposed for 13 seconds, 4 months post infection, followed by 92.5% and 87.2% in the same group, two and three months post infection.

**Keywords:** Echinococcus granulosus, microwave, Hydatidosis, BALB/c Mice

## 1. Introduction

Cystic echinococcosis (CE, also known as hydatid disease) is a neglected zoonotic tropical illness that is predicted to cause the death of millions of people each year (1). Infection with the larval stages of platyhelminthes (flatworms) belonging to the taenidae family, notably the genus Echinococcus, causes it. The condition is characterized by the formation of fluid-filled, bladder-like larvae within internal organs. These are referred to as hydatid cysts, or more accurately, hydatids, because the term 'cyst' refers to both the parasite and the local host reaction. At least three Echinococcus species cause human CE, and only molecular biology methods can tell them apart. *E. granulosus sensu stricto* and *E. canadensis* are responsible for about 90% and 10% of cases, respectively. *E. granulosus sensu lato* refers to the species cluster (which also includes two other species). The genus Echinococcus contains several species, the most important of which is Echinococcus multilocularis, which causes alveolar echinococcosis, in which the larva invades the liver parenchyma aggressively (2). Echinococcus species have two life-cycles: one with one host and one with the other host (3). Adult stages of *E. granulosus sensu lato* (worms measuring only a few millimeters in length) develop in the small intestine of carnivore hosts, which are usually dogs. The so-called intermediate hosts are infected by eggs transmitted out with dog feces. Sheep, cows, pigs, camels, goats, buffaloes, and cervids, as well as humans, make up the intermediate host range. Eggs hatch in the intestine, releasing oncospheres that puncture the gut wall, travel by blood or lymph, and settle in internal organs, eventually forming hydatids. Hydatids can generate protoscoleces, which are parasitic forms, within months or years. When dogs eat infected tissues from

intermediate hosts, the parasites' life cycles are completed: eaten protoscoleces mature into adult worms in the gut. Within *E. granulosus sensu lato*, each species (and subspecies) has a favored intermediate host species range (3). Sheep are *E. granulosus sensu stricto*'s favored intermediate hosts. Because human infection plays no role in the life-cycles, humans are considered incidental or aberrant intermediate hosts. Except for Antarctica, CE is found on every continent. The infection is highly related with livestock rearing in undeveloped situations, as expected given the life-cycle pattern outlined. North Africa, the near and Middle East, Central Asia, eastern Russia, and western China have the highest disease burdens; South America, while still heavily afflicted, has seen the prevalence of CE decline in recent decades. (4, 5).

Chemotherapy and surgery are now used to treat hydatid illness. Because of the numerous layers of cyst, antiparasite therapy has a hard time penetrating and killing protoscoleces in cystic echinococcosis (6, 7). As a result, the antiparasite medication can only be taken as a last resort. The most common treatment is still surgery (8, 9). To aspirate daughter cysts and inject antihelminthic agent, the parasite cyst must be opened.

Surgical methods have increasingly evolved from destructive to constructive in recent years. The minimally invasive treatment has a high cure rate and low morbidity and fatality rates (10). WHO has advocated PAIR (puncture aspiration injection reaspiration) as an alternate treatment for hydatid cysts? In terms of disease recurrence, morbidity, and death, PAIR plus chemotherapy outperforms open surgery (11, 12). New minimally invasive therapeutic approaches for hydatid cyst ablation have been introduced in recent years, such as radio frequency [13], microwave (14), cryoablation [15], and HIFU (16–19).

As a result, it appears that microwave radiation may impact protoscoleces and may be useful in the treatment of hydatidosis or the prevention of secondary cyst recurrence. Microwaves are non-ionizing electromagnetic radiation that are very brief waves of electromagnetic energy (20). Many studies have shown that microwaves are effective at killing bacteria (21-23). Microwaves can create two types of impacts, according to the literature: thermal and non-thermal [23]. Microwave therapy makes advantage of the thermal effects of microwaves (24). Microwave irradiation is used to heat bodily tissues and kill cancer cells, or to make cancer cells more sensitive to the effects of other types of radiation and/or particular anticancer medications, in this type of treatment (25, 26).

In this study the effect of microwave radiation on hydatid cyst has been investigated, we evaluated the effects of this kind of waves on protoscoleces in vitro, and on growth and development of hydatid cysts in vivo.

## 2. Materials and Methods

### Isolation and testing hydatid cysts

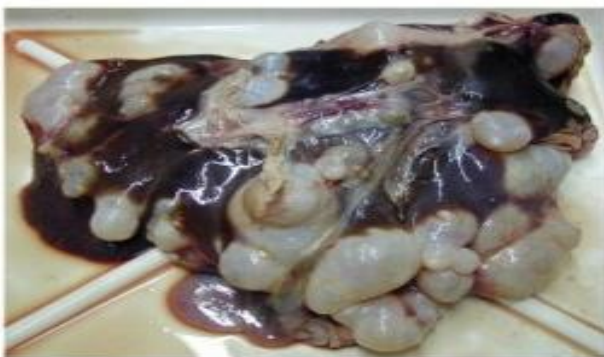

Figure 1: Larval stages (hydatid cysts) in the liver of sheep.

Hydatid cysts were obtained (Figure 1) after being separated from livers of slaughtered sheep in the main abattoir in Mosul, upon arrival to the laboratory, hydatid cysts were examined to accentual the vitality of protoscoleces.

Collection and assessment of E. granulosus protoscoleces

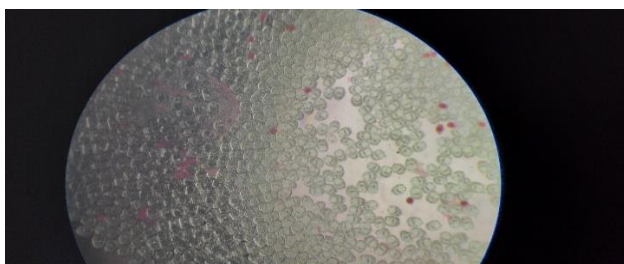


Fig 2. Protoscoleces of Echinococcus granulosus

Sheep cysts containing protoscoleces were obtained under sterilized conditions, a live protoscoleces, 20 µl of protoscoleces suspension were added to 20 µl of 0.1% of eosin pigment on a slide, then tested under light microscope. Bright green protoscoleces were considered as alive because of eosin exclusion by protoscoleces membranes, whereas red protoscoleces were regarded as dead regarding to

the acceptance of the pigment (Fig 2). Gained and counted according to authenticated manner (27).

### Experimental animals

120 female Albino mice, BALB/c (three to four weeks old) were used and cared for in the animal house, College of Veterinary Science, University of Mosul, according to the conditions required for the experiments.

The system used in the experiment



Fig 3. Microwave system

Microwave system (230-240V-50Hz 900W) (Fig 3) was used

Power 2. Minute, second 3. Start 4. Stop

### Experimental Design

#### Effect of the microwave on the vitality of sheep protoscoleces in vitro

To determine the effect of microwave on the vitality of protoscoleces in vitro within different durations, protoscoleces with a 98-100% viability were taken at a concentration of 2000 protoscoleces /ml, and then exposed continuously to the microwave waves, in test tubes, Samples were exposed, in a continuous manner, for 3, 5, 7, 10, 12, 13, 15 seconds, respectively. The post exposure vital percentages were 90%, 80%, 77%, 70%, 50, 30 and 0%, respectively (Table 1, 2). The protoscoleces were examined under a light microscope for viability taking into consideration the flame cells movement, morphological abnormalities, and exclusion of eosin pigment.

| 15 Sec | 13 Sec | 12 Sec | 10 Sec | 7 Sec | 5 Sec | 3 Sec | Control | Frequency/ Time |
|--------|--------|--------|--------|-------|-------|-------|---------|-----------------|
| 0%     | 30%    | 50%    | 70%    | 77%   | 80%   | 90%   |         | 50Hz 900W       |

| P      | F         | MS       | SS        | DF | Source  |
|--------|-----------|----------|-----------|----|---------|
| 0.0001 | 2907.33** | 2989.651 | 17937.909 | 6  | Treated |
|        |           | 1.028    | 28.792    | 28 | Error   |
|        |           |          | 17966.702 | 34 | Total   |

\*\* mean significance at P<0.01, while \* mean significance of P<0.05

#### Effect of ultrasound waves on secondary hydatid disease in mice

Protoscolices with vitality 30%, 50%, 70%, were selected for mice injection in addition to the control with 100% vitality. A total of 60 female mice, aged 5-3 weeks, were divided into four groups (fifteen mice/

each group). The 1st group was injected with 2000 protoscoleces of vitality 30%. The 2nd was injected with 2000 protoscoleces of vitality 50%. The 3rd was injected with 2000 protoscoleces of vitality 70%. The 4th group was injected with 2000 protoscoleces of vitality 100% (control group). All groups were all dissected after two, three, four months post injection, respectively.

After dissection, the numbers, weights and diameters of hydatid cysts were detected, in addition to their percentage of reduction according to the equation

Percentage reduction of hydatid cysts

$$100 - \frac{\text{Number of hydatid cysts in treated mice}}{\text{number of cysts in control group}} \times 100$$

Statistical analysis

Results of this study were analyzed statistically based on Completely Randomized Design (CRD) to study the effect of intervals and exposures and the integration between them, then the differences

between the averages of each factor and the compatibility between factors were estimated depending on Duncan's Multiple Range Test (DMRT). Statistical Analysis System (SAS version 9) was utilized for applied for data analysis (28).

3. Results

Table 3 reveals the changes in the number of hydatid cysts, their diameters, and weights, as well as the significance of F in the ANOVA analysis. the DMRT for averages test (Table 4) explained a decrease in the average number of in the treated groups (Figure 4, 5, 6, 8, 9, 10), When compared to the control animals (Figure 7, 11). The number of cysts in treated mice decreased by 1.0 after 13 seconds of exposure, while the control animals had the highest average of 42.2, 4 months after infection. Table 5 demonstrated the highest percentage reduction of hydatid cysts 97% in treated mice followed by 92.2% and 87% after 13 seconds exposure respectively.

**Table 3: Effect of microwaves on numbers, weights and diameters of hydatid cysts in all of ثءءءق hydatid cysts in all exweights and diameters of hydatid cysts in all exexperience animals**

| Experimental Error   | Periods Treatment <sup>x</sup>  | Treatments | Periods | Sources of difference |
|----------------------|---|------------|---------|-----------------------|
| 48                   | 6   | 3          | 2       | df                    |
| 2336.40<br>48.6750   | 1733.6 5945.25 2688.93 Sum of squares<br>Mean squares 1344.46** 1981.75** 288.93**<br>5.9440.7F value 27.6      |            |         | Cysts number          |
| 0.095704<br>0.001993 | Sum of squares 0.020721 0.02917 0.02708<br>Mean squares 0.010360** 0.00972** 0.00451*<br>F value 5.20 4.88 2.26 |            |         | Cysts weight(gm)      |
| 5.6259<br>0.11720    | Sum of squares 20.1241 17.1953 7.5188<br>Mean squares 10.0620** 5.73177** 1.2531**<br>F value 85.85 48.9 10.69  |            |         | Cysts diameters (mm)  |

\*\* mean significance at P<0.01, while \* mean significance of P<0.05

**Table 4: Effect of microwaves on the number of hydatid cysts in treated animals**

| Average  | 4 months  | 3 months   | 2 months  | periods   |
|----------|-----------|------------|-----------|-----------|
| 28.667 a | 42.200 a  | 35.800 a   | 8.000 bcd | Control   |
| 9.267 b  | 17.800 b  | 8.000 bcd  | 2.000 d   | 10 second |
| 8.467 b  | 14.000 bc | 10.200 bcd | 1.200 d   | 12 second |
| 2.067 c  | 1.000 d   | 4.600 cd   | 0.600     | 13 second |
|          | 8.750 a   | 4.650 a    | 2.950 b   | Average   |

The different letters indicate significance, while the similar letters indicate insignificance.

**Table 5: Percentage of hydatid cysts reduction in treated animals for all months**

| 4 months | 3 months | 2 months | Periods |
|----------|----------|----------|---------|
| 57.9%    | 77.7%    | %75      | 10 Sec  |
| 66.9%    | 71.6%    | 85%      | 12 Sec  |
| 97%      | 87.2%    | 92.5%    | 13 Sec  |

**Table 6: Effect of microwaves on the weight of hydatid cysts in treated animals**

| Average   | 4 months  | 3 months  | 2 months  | Periods |
|-----------|-----------|-----------|-----------|---------|
| 0.05780 a | 0.13200 a | 0.04000 b | 0.00140 b | Control |
| 0.01227b  | 0.02600 b | 0.01000 b | 0.00080 b | 10 Sec  |
| 0.01033 b | 0.02200 b | 0.00820 b | 0.00080 b | 12 Sec  |
| 0.00093 b | 0.00140 b | 0.00100 b | 0.00040 b | 13 Sec  |
|           | 0.04535 a | 0.01480 b | 0.00085 b | Average |

The different letters indicate significance, while the similar letters indicate insignificance.

**Table 7: Effect of microwaves on the diameters of hydatid cysts in treated animals**

| 4 months | 3 months  | Periods 2 months  |
|----------|-----------|-------------------|
| 2.8200 a | 1.3640 c  | Control 0.8840 d  |
| 2.3000 b | 0.8820 d  | 10 Sec 0.6200 def |
| 2.2000 b | 0.7000 de | 12 Sec 0.4200 def |
| 0.1600 f | 0.3600 ef | 13 Sec 0.1400 f   |
| 1.8700 a | 0.8265 b  | Average 0.5160 c  |

The different letters indicate significance, while the similar letters indicate insignificance.

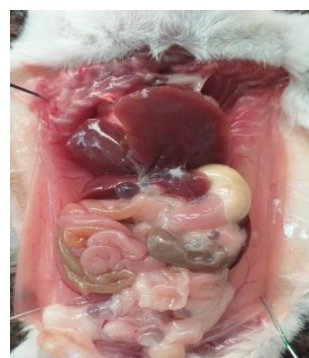

Fig 4: hydatid cysts in t mice injected with exposed protoscoleces for 10 seconds, four months post infection

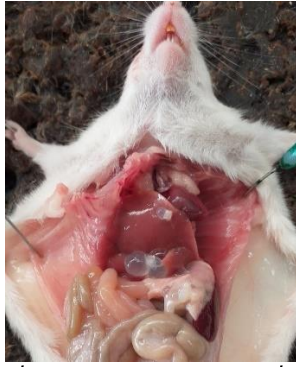

Fig 4: hydatid cysts in t mice injected with exposed protoscoleces for 12 seconds, four months post infection

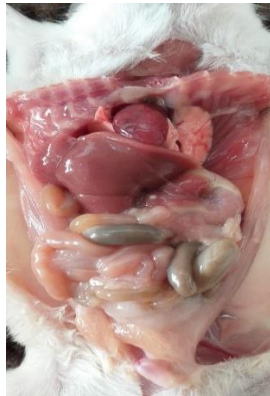

Fig 6: hydatid cysts in t mice injected with exposed protoscoleces for 13 seconds, four months post infection

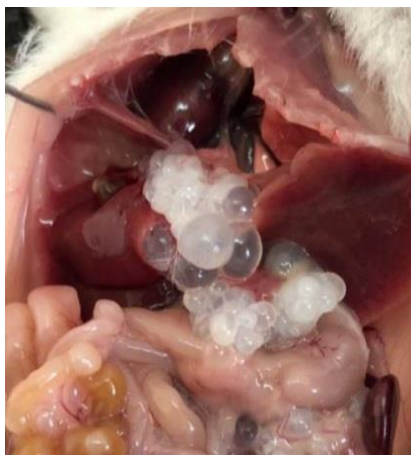

Fig 7: Hydatid cysts in mice injected with unexposed protoscoleces (control group) 4 months post infection

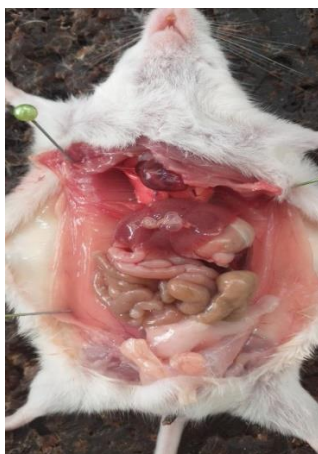

Fig 8: Hydatid cysts in t mice injected with exposed protoscoleces for 10 seconds, three months post infection

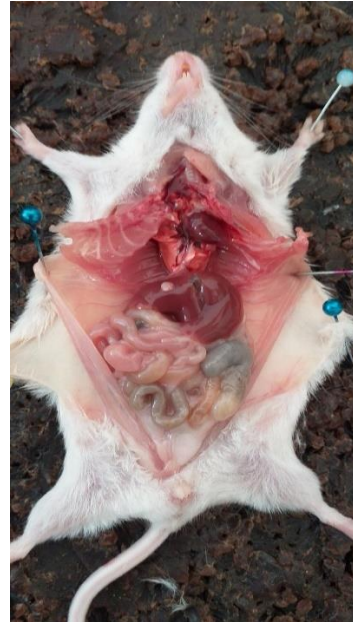

Fig 9: Fig 6: hydatid cysts in mice injected with exposed protoscoleces for 12 seconds, three months post infection

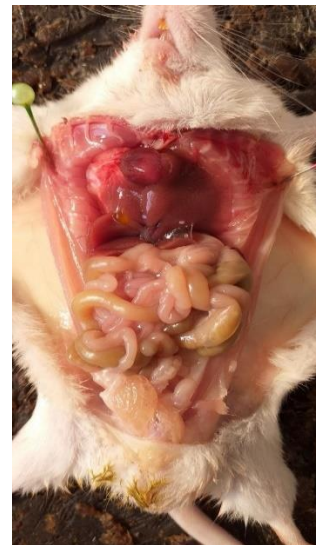

Fig 10: hydatid cysts in t mice injected with exposed protoscoleces for 13 seconds, three months post infection

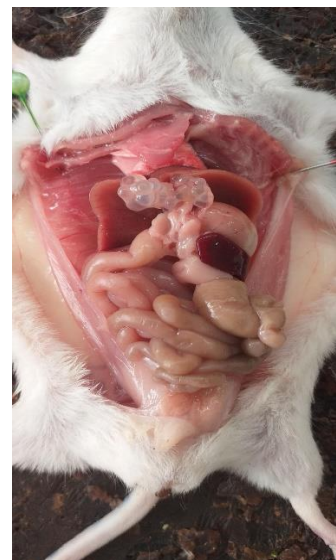

Fig 11: Hydatid cysts in mice injected with unexposed protoscoleces (control group) three months post infection

## 4. Discussion

MWA is a common interventional technique that uses a heat action to cause coagulation necrosis in the target lesion. During MWA, the active tip produces an oscillating electromagnetic field that radiates into the tissue around the antenna, forcing polar molecules (mainly H<sub>2</sub>O) to realign continually, boosting their kinetic energy and, as a result, causing direct tissue heating (29).

MWA was first described by Seki et al (30), and it has since been routinely used to treat primary hepatocellular carcinoma. Despite the fact that the friction of intracellular and extracellular charged ions is caused by microwave frequency and collisions with other molecules, the local temperature rises above 65°C in a short amount of time, resulting in coagulation necrosis. MWA may also boost immunological function by promoting the generation of Th1 cells. (31).

Yangdan Cairang (2017) Efficacy and safety of ultrasound – guided percutaneous

The hepatic alveolar echinococcosis HAE lesions gradually calcify after microwave treatment, according to Yangdan Cairang et al. (2017, 32), with no major problems or recurrence after surgery.

The advancement of numerous medical technology has enabled radio frequency electromagnetic as a non-invasive method (33). The influence of an electromagnetic field (REF) on a cell membrane causes alterations in ion transport across the membrane, according to the researchers (34). A cell's membrane might also become more fluid (35), (36). The cell's permeability was altered, perhaps allowing certain potentially hazardous molecules to enter as well as greater protein and other molecule mobility in and through the membrane (37). High temperatures can damage both integral and peripheral proteins in the membrane, and excessive heat can cause these proteins to break down, or denature (34).

Hyperthermia, either local or whole-body, has been suggested as a treatment for various malignant tumors in several studies. Microwave application is one of the most effective means of producing hyperthermia. In regions with a shallow depth, these waves quickly elevated temperature (32). Eslamirad et al. (38) employed a different method called shortwave diathermy (SWD) to heat deep laying tissues and a big volume of tissue. In length deep, SWD can cause heat.

The current study found that microwave irradiation can harm protoscoleces, and that this effect is depending on the duration and manner of irradiation. Electromagnetic radiations like UV, gamma rays, lasers, and microwaves have recently been employed to cure ailments. In addition, some studies have found that electromagnetic waves alter cell proliferation, cell function, chromosomal number, and cell membrane permeability (39, 40). Microwave electromagnetic radiation has been found in various studies to have harmful effects on

biological tissue, however, the intended effects of these waves in the therapy of certain disorders have been demonstrated and have been used in diathermy (38). In another study, the thermal effects of microwave radiation on bacteria's ultrastructure were investigated. Microbiological investigations have demonstrated that cells die when exposed to microwaves. Temperature increases have been identified as the primary cause of cell death in these situations (22).

Although most scientists are concerned about the dangers of microwave waves, some have concentrated on using them to kill pathogenic organisms and treat ailments like hydatid cysts and protoscoleces. LAMonaca et al. (13) found that RF can be used to necrotize the germinal layer of a hydatid cyst. Then, by raising the temperature of the cyst to 95 °C, Saricik et al. (41) discovered that the RF technique might harm the germinal layer of a hydatid cyst (after 4-minute exposure). Although the germinal layer of hydatid cysts must be damaged with intense heat, other organs and blood arteries may be damaged as a result of the heat (42). Protoscoleces exposed to mobile phone radiation exhibited a greater mortality rate than those not exposed, according to Soleimani et al. (43). The parasite's mortality rate is also affected by its distance from the mobile phone and the length of time it is exposed to its radiation. 2020 Soleimani et al.

## 5. Conclusion

It may well be concluded ultrasound has a significant impact on the viability of protoscoleces of Echinococcus granulosus in vitro and in BALB/c mice, and against growth and development of hydatid disease in experimental animals, so it may be used in the future as a promising therapeutic method for cystic echinococcosis.

## Acknowledgement

The researchers would like to acknowledge Education College for Pure Sciences, University of Mosul for supporting the current research.

Conflict of interests

The authors declare no conflict of interest

## References

- Agudelo Higuera NI, Brunetti E, McCloskey C. Cystic echinococcosis. *J Clin Microbiol* 2016; 54:518–23. Doi:10.1128/JCM.02420-15
- Kern P, Menezes da Silva A, Akhan O, et al. The echinococcoses: diagnosis, clinical management and burden of disease. *Adv Parasitol* 2017; 96:259–369. *Immunology of cystic echinococcosis*, 2017 96:259–369. doi: 10.1016/bs.apar.2016.09.006. Epub 2017 Feb 8.
- Thompson RC. Biology and systematics of Echinococcus. *Adv. Parasitol* 2017; 95:65–109. DOI:10.1016/bs.apar.2016.07.001
- Craig PS, Hegglin D, Lightowers MW, et al. Echinococcosis: control and prevention. *Adv Parasitol* 2017;96: 55–158. Doi:

- 10.1016/bs.apar.2016.09.002. Epub 2016 Dec 28.
5. Cucher MA, Macchiaroli N, Baldi G, et al. Cystic echinococcosis in South America: systematic review of species and genotypes of *Echinococcus granulosus sensu lato* in humans and natural domestic hosts. *Trop Med Int Health* 2016;21: 166–75. doi: 10.1111/tmi.12647. Epub 2015 Dec 28.
  6. Chen, X., Zhang, R., & Wen, H. (2018). Experimental nanopulse ablation of multiple membrane parasite on ex vivo hydatid cyst. *BioMed research international*, 2018. DOI:[10.1155/2018/8497283](https://doi.org/10.1155/2018/8497283).
  7. D. A. Vuitton, A. Azizi, C. Richou et al., "Current interventional strategy for the treatment of hepatic alveolar echinococcosis," *Expert Review of Anti-infective Therapy*, vol. 14, no. 12, pp. 1179–1194, 2016. doi: 10.1080/14787210.2016.1240030.
  8. X. Chen, X. Chen, Y. Shao, J. Zhao, H. Li, and H. Wen, "Clinical outcome and immune follow-up of different surgical approaches for human cyst hydatid disease in liver," *The American Journal of Tropical Medicine and Hygiene*, vol. 91, no. 4, pp. 801–805, 2014. doi: 10.4269/ajtmh.14-0177.
  9. Wan, L., Ran, B., Aji, T., Shalayiadang, P., Jiang, T., Shao, Y., & Wen, H. (2021). Laparoscopic hepatectomy for the treatment of hepatic alveolar echinococcosis. *Parasite*, 28:5 DOI: [10.1051/parasite/2021001](https://doi.org/10.1051/parasite/2021001)
  10. X. Chen, C. Cen, H. Xie, L. Zhou, H. Wen, and S. Zheng, "The comparison of 2 new promising weapons for the treatment of hydatid cyst disease: PAIR and laparoscopic therapy," *Surgical Laparoscopy Endoscopy & Percutaneous Techniques*, vol. 25, no. 4, pp. 358–362, 2015. DOI: [10.1097/SLE.000000000000177](https://doi.org/10.1097/SLE.000000000000177).
  11. A. Nayman, I. Guler, S. Keskin et al., "A novel modified PAIR technique using a trocar catheter for percutaneous treatment of liver hydatid cysts: A six-year experience," *Diagnostic and Interventional Radiology*, vol. 22, no. 1, pp. 47–51, 2016. DOI:[10.5152/dir.2015.15011](https://doi.org/10.5152/dir.2015.15011)
  12. C. Gomez i Gavara, R. Lopez-And ´ ujar, T. Belda lb ´ a ´ nez et al., "Review of the treatment of liver hydatid cysts," *World Journal of Gastroenterology*, vol. 21, no. 1, pp. 124–131, 2015. doi: [10.3748/wjg.v21.i1.124](https://doi.org/10.3748/wjg.v21.i1.124)
  13. Lamonaca, V., Virga, A., Minervini, M. I., Di Stefano, R., Provenzani, A., Tagliareni, P., ... & Gridelli, B. (2009). Cystic echinococcosis of the liver and lung treated by radiofrequency thermal ablation: an ex-vivo pilot experimental study in animal models. *World journal of gastroenterology: WJG*, 15(26), 3232. doi: [10.3748/wjg.15.3232](https://doi.org/10.3748/wjg.15.3232).
  14. D. J. Christian, A. Khithani, and D. R. Jeyarajah, "Making liver transection even safer: a novel use of microwave technology," *The American Surgeon*, vol. 77, no. 4, pp. 417–421, 2011. <https://doi.org/10.1177/000313481107700415>.
  15. J. H. M. B. Stoot, C. K. Jongsma, I. Limantoro, O. T. Terpstra, and P. J. Breslau, "More than 25 years of surgical treatment of Hydatid cysts in a non-endemic area using the "frozen seal" method," *World Journal of Surgery*, vol. 34, no. 1, pp. 106–113, 2010.
  16. S. B. Imankulov, G. V. Fedotovskikh, G. M. Shaimardanova, M. Yerlan, and N. K. Zhampeisov, "Feasibility study of high intensity focused ultrasound (HIFU) for the treatment of hydatid cysts of the liver," *Ultrasonics Sonochemistry*, vol. 27, pp. 712–716, 2015. DOI: [10.1016/j.ultsonch.2015.05.025](https://doi.org/10.1016/j.ultsonch.2015.05.025)
  17. A.-B. Liu, H. Cai, B. Ye et al., "The damages of high intensity focused ultrasound to transplanted hydatid cysts in abdominal cavities of rabbits with aids of ultrasound contrast agent and superabsorbent polymer," *Parasitology Research*, vol. 112, no. 5, pp. 1865–1875, 2013. DOI: [10.1007/s00436-013-3340-4](https://doi.org/10.1007/s00436-013-3340-4)
  18. H. Cai, L.-L. Chen, B. Ye, A.-B. Liu, J. Zhang, and Y.-F. Zhao, "The destructive effects of high-intensity focused ultrasound on hydatid cysts enhanced by ultrasound contrast agent and superabsorbent polymer alone or in combination," *Parasitology Research*, vol. 112, no. 2, pp. 707–717, 2013.
  19. X. Zou, J. Wang, H. Zhao, J. Zhang, W. Wu, and B. Ye, "Echinococcus granulosus: protoscolicidal effect of high intensity focused ultrasound," *Experimental Parasitology* emphasizes, vol. 121, no. 4, pp. 312–316, 2009. DOI: [10.1016/j.exppara.2008.12.002](https://doi.org/10.1016/j.exppara.2008.12.002)
  20. Eslamirad, Z., Soleimani, H., Hajhossein, R., & Rafiei, F. (2015). Evaluation of lethal effect of microwave exposure on protoscolices of hydatid cyst in vitro. *Asian Pacific Journal of Tropical Disease*, 5(10), 821-824. [https://doi.org/10.1016/S2222-1808\(15\)60938-0](https://doi.org/10.1016/S2222-1808(15)60938-0).
  21. Celandroni F, Longo I, Tosoratti N, Giannessi F, Ghelardi E, Salvetti S, et al. Effect of microwave radiation on *Bacillus subtilis* spores. *J Appl Microbiol* 2004; 97(6): 1220-7. DOI: [10.1111/j.1365-2672.2004.02406.x](https://doi.org/10.1111/j.1365-2672.2004.02406.x)
  22. Kim SY, Jo EK, Kim HJ, Bai K, Park JK. The effects of high-power microwaves on the ultrastructure of *Bacillus subtilis*. *Lett Appl Microbiol* 2008; 47(1): 35-40. doi: 10.1111/j.1472-765X.2008.02384.x.
  23. Woo IS, Rhee IK, Park HD. Differential damage in bacterial cells by microwave radiation on the basis of cell wall structure. *Appl Environ Microbiol* 2000; 66(5): 2243-7. DOI:[10.1128/AEM.66.5.2243-2247](https://doi.org/10.1128/AEM.66.5.2243-2247).
  24. Banik S, Bandyopadhyay S, Ganguly S. Bioeffects of microwave—a brief review. *Bioresour Technol* 2003; 87(2): 155-9. [https://doi.org/10.1016/S0960-8524\(02\)00169-4](https://doi.org/10.1016/S0960-8524(02)00169-4).
  25. Giombini A, Giovannini V, Di Cesare A, Pacetti P, Ichinoseki-Sekine N, Shiraishi M, et al. Hyperthermia induced by microwave diathermy in the management of muscle and tendon injuries. *Br Med Bull* 2007; 83: 379-96. doi: 10.1093/bmb/ldm020.
  26. Sterzer F, inventor; Mmtc, Inc., assignee. Method for enhancing delivery of chemotherapy employing high-frequency force fields. United States patent US5386837 A. 1995 Feb 7. <https://patents.google.com/patent/US5386837>.
  27. Smyth JD, Barrett NJ. Procedures for testing the viability of human hydatid cysts following surgical

- removal, especially after chemotherapy. *Trans Royal Soc Trop Med Hyg.* 1980; 74(5), 649-652. Doi: 10.1016/0035-9203(80)90157-1.
28. Al-Zubaidy KM, Al-Falahy MD. Principles and procedures of statistics and experimental design. 1st ed. Duhok: University of Duhok Printing Press; 2016. 395 p.
29. Wa, Z. C., Du, T., Hu, H. T., & Lu, M. D. (2020). Microwave ablation combining surgery for the treatment of multi organ cystic echinococcosis: A case report. *Parasitology international*, 74, 101921. DOI: [10.1016/j.parint.2019.04.018](https://doi.org/10.1016/j.parint.2019.04.018)
30. Seki T, Wakabayashi M, Nakagawa T, et al. Ultrasonically guided percutaneous microwave coagulation therapy for small hepatocellular carcinoma. *Cancer* 1994;74:817-25. DOI: [10.1002/1097-0142\(19940801\)74:3](https://doi.org/10.1002/1097-0142(19940801)74:3).
31. Taradi M, Urano M, Taradi SK, et al. Augmentation of mouse natural killer cell activity by combined hyperthermia and streptococcal preparation, OK-432 (Picibanil) treatment. *Int J Hyperthermia* 1991; 7: 653-65. <https://doi.org/10.3109/02656739109034977>
32. Cairang, Y., Zhang, L., Ren, B., Ren, L., Hou, L., Wang, H., ... & Fan, H. (2017). Efficacy and safety of ultrasound-guided percutaneous microwave ablation for the treatment of hepatic alveolar echinococcosis: A preliminary study. *Medicine*, 96(27). doi: 10.1097/MD.0000000000007137
33. Zimmerman JW, Jimenez H, Pennison MJ, Brezovich I, Morgan D, Mudry A, et al. Targeted treatment of cancer with radiofrequency electromagnetic fields amplitude-modulated at tumor-specific frequencies. *Chin J Cancer.* 2013;32(11):573-81. <https://doi.org/10.5732/cjc.013.10177> PMID:24206915.
34. Lucia U, Ponzetto A, Deisboeck TS. Constructral approach to cell membranes transport: Amending the "Norton-Simon" hypothesis for cancer treatment. *Sci Rep.* 2016; 6:19451. <https://doi.org/10.1038/srep19451> PMID:26822208
35. Monzel C, Sengupta K. Measuring shape fluctuations in biological membranes. *J Phys D.* 2016;49(24):243002. <https://doi.org/10.1088/0022-3727/49/24/243002>
36. Hanna H, Denzi A, Liberti M, André FM, Mir LM. Electropermeabilization of inner and outer cell membranes with microsecond pulsed electric fields: Quantitative study with calcium ions. *Sci Rep.* 2017;7(1):13079. <https://doi.org/10.1038/s41598-017-12960-w> PMID:29026094.
37. Greenebaum B, Barnes F. Bioengineering and Biophysical Aspects of Electromagnetic Fields. 4th ed. Florida, United States: CRC Press; 2018.
38. Eslamirad, Z., Hajihosseini, R., & Soleimani, H. (2020). Is Shortwave Diathermy Effective on Mortality of Protoscolices?. *Open Access Macedonian Journal of Medical Sciences*, 8(A), 55-58. DOI <https://doi.org/10.3889/oamjms.2020.3816>.
39. Skamrova GB, Lantushenko AO, Shckorbatov YG, Evstigneev MP. Influence of mobile phone radiation on membrane permeability and chromatin state of human buccal epithelium cells. *Biochem Biophys* 2013; 1(2): 22-8. [www.seipub.org/bab](http://www.seipub.org/bab)
40. Rougier C, Prorot A, Chazal P, Leveque P, Leprat P. Thermal and non thermal effects of discontinuous microwave exposure (2.45 gigahertz) on the cell membrane of Escherichia coli. *Appl Environ Microbiol* 2014; 80(16): 4832-41. DOI: [10.1128/AEM.00789-14](https://doi.org/10.1128/AEM.00789-14)
41. Saricik B, Kartal A, Esen H, Demircili ME. The Use of Radiofrequency Thermal Ablation Method in The Treatment of Hepatic Hydatid Cysts: Ex vivo Sheep Study. *Türkiye Parazitoloj Derg* 2019; 43: 10-5. DOI: [10.4274/tpd.galenos.2019.5461](https://doi.org/10.4274/tpd.galenos.2019.5461)
42. Pillai K, Akhter J, Chua TC, Shehata M, Alzahrani N, Al-Alem I, et al. Heat sink effect on tumor ablation characteristics as observed in monopolar radiofrequency, bipolar radiofrequency, and microwave, using ex vivo calf liver model. *Medicine* 2015; 94: e580. DOI: [10.1097/MD.0000000000000580](https://doi.org/10.1097/MD.0000000000000580)
43. Soleimani H, Hajihosseini R. and Eslamirad, Z. (2020). Mobile Phone Radiation: Its Efficacy as Protoscolicidal. *Türkiye Parazitolojii Dergisi*, 44(4), 203. DOI: [10.4274/tpd.galenos.2020.6722](https://doi.org/10.4274/tpd.galenos.2020.6722)